

# Clinically detectable structural abnormalities in pediatric-onset multiple sclerosis: A large-scale magnetic resonance imaging analysis

Jacob Levman<sup>1</sup>  | Avilash Das<sup>2</sup> | Allissa MacDonald<sup>3</sup> | Patrick MacDonald<sup>2</sup> | Lindsay Berrigan<sup>4</sup> | Emi Takahashi<sup>2</sup>

<sup>1</sup>Department of Computer Science, St. Francis Xavier University, Antigonish, NS, Canada

<sup>2</sup>Division of Newborn Medicine, Department of Medicine, Boston Children's Hospital, Harvard Medical School, Boston, MA, USA

<sup>3</sup>Department of Biology, St. Francis Xavier University, Antigonish, NS, Canada

<sup>4</sup>Department of Psychology, St. Francis Xavier University, Antigonish, NS, Canada

## Correspondence

Jacob Levman, Canada Research Chair in Bioinformatics, St. Francis Xavier University, 5005 Chapel Square, Antigonish, NS B2G 2W5, Canada.  
Email: jlevman@stfx.ca

## Funding information

St. Francis Xavier University, Grant/Award Number: Startup grant R0168020; Natural Sciences and Engineering Research Council of Canada, Grant/Award Number: Canada Research Chair 231266 and Discovery Grant R0192004; Nova Scotia Research Innovation Trust, Grant/Award Number: R0176004; National Institutes of Health, Grant/Award Number: HD098606, R01HD078561, R03NS091587 and R21MH118739; Canada Foundation for Innovation, Grant/Award Number: R0176004

## Abstract

**Background:** Multiple Sclerosis is characterized by neural demyelination. Structural magnetic resonance imaging (MRI) provides soft tissue contrast, which forms the basis of techniques for extracting regional biomarkers across a participant's brain.

**Objectives:** To investigate the clinical presentation of multiple sclerosis in a large-scale MRI analysis that includes thorough consideration of extractable structural measurements (average and variability of regional cortical thicknesses, cortical surface measurements, and volumes).

**Methods:** We performed a large-scale retrospective analysis of 370 T1 structural volumetric MRIs from 64 participants with multiple sclerosis and compared them with a large cohort of neurotypical participants, consisting of 993 MRIs from 988 participants. Regionally distributed measurements of cortical thickness (average and standard deviation) were extracted along with surface area, surface curvature, and volumetric measurements.

**Results:** The largest observed finding involved regionally distributed reductions in average cortical thickness, with the parahippocampal region exhibiting the largest effect size, a finding that may be linked with known hippocampal atrophy in multiple sclerosis. Group-wise differences were also observed in terms of distributed volume, surface area, and surface curvature measurements.

**Conclusions:** Participants with pediatric-onset multiple sclerosis present clinically with a variety of structural abnormalities, including perirhinal cortex thickness abnormalities not previously reported in the literature.

## KEYWORDS

cortical thickness, magnetic resonance imaging, multiple sclerosis, neuroanatomy

Jacob Levman and Avilash Das denotes co-primary authors

© 2021 International Society for Developmental Neuroscience

## 1 | INTRODUCTION

Pediatric-onset multiple sclerosis (POMS) occurs prior to age 18 and represents ~3%–5% of all MS cases (Renoux et al., 2007). Like adult-onset MS, POMS is characterized by demyelination within the central nervous system and gray matter atrophy; however, inflammatory lesions accrue more rapidly (Bermel et al., 2003; Filippi et al., 2012; Ge et al., 2007; Henry et al., 2008; Parmar et al., 2018; Ricciteli et al., 2012). Factors such as demyelination and neuronal loss are thought to underlie cortical atrophy, which serve as predictors of long-term disability and quality of life. Regional structural changes have been observed in POMS in the subcortical gray matter, including in the thalamus, hypothalamus, putamen, and caudate (Bermel et al., 2003; Ge et al., 2007; Henry et al., 2008), atrophy of which has been suggested to be a measurable result of Wallerian degeneration (Henry et al., 2008). Posterior white matter atrophy affecting the brainstem and the cerebellum has also been reported (Ricciteli et al., 2012), findings that could be linked with known motor deficiencies in MS.

The use of magnetic resonance imaging (MRI) techniques has been crucial in defining the pathology and severity of the disease (Bakshi et al., 2008). In the brain, MRI provides for the ability to differentiate between gray matter, white matter, and cerebrospinal fluid, which forms the basis for the extraction of biomarkers across brain regions, such as white and gray matter volumes, cortical thickness, cortical folding/gyration-based measures, and cortical surface area (e.g., Fischl, 2012). Using MRI, many investigators have quantified the rate of atrophy in MS at various stages of the disease. Many studies suggest localized regional atrophy is a more sensitive gauge of MS progression and disease state than global atrophy (Bakshi et al., 2001; Bergsland et al., 2012; Houtchens et al., 2007; Mesaros et al., 2008; Sepuclre et al., 2006). Modern MRI techniques and post-processing methods, such as automated quantification (e.g., Fischl, 2012), have allowed for the systematic assessment of regional cortical atrophy (Ceccarelli et al., 2008; Deppe et al., 2016; Sailer et al., 2003; Steenwijk et al., 2016). Furthermore, existing studies have identified hippocampal abnormalities being associated with MS (Anderson et al., 2010; Hulst et al., 2015; Longoni et al., 2015; Rocca et al., 2016), which we will further investigate as part of this analysis. Volume reductions in the corpus callosum, cerebellum, amygdala, and particularly the thalamus, have also been reported in POMS (Parmar et al., 2018). While automated quantification methods provide multiple biomarkers by which the brain can be assessed, most studies only focus on one type of biomarker, such as volumetric measures or measures of average cortical thicknesses. In this work we incorporated all the available average cortical thicknesses, variability in cortical thicknesses, regional volumetric

measurements, and regional surface measurements, making this study considerably more thorough than many found in the literature.

In this study, we hypothesize that analysis of the presentation of the brains of participants with POMS can help to identify group-wise abnormalities of regional brain measurements potentially associated with POMS, can help to identify biomarkers with potential to contribute to next-generation diagnostic technologies, and can provide a reference for what to expect from a clinical POMS population. Because of the relatively large number of scans included in this study, we aim to clinically validate the patterns of atrophy identified by other investigators.

## 2 | MATERIALS AND METHODS

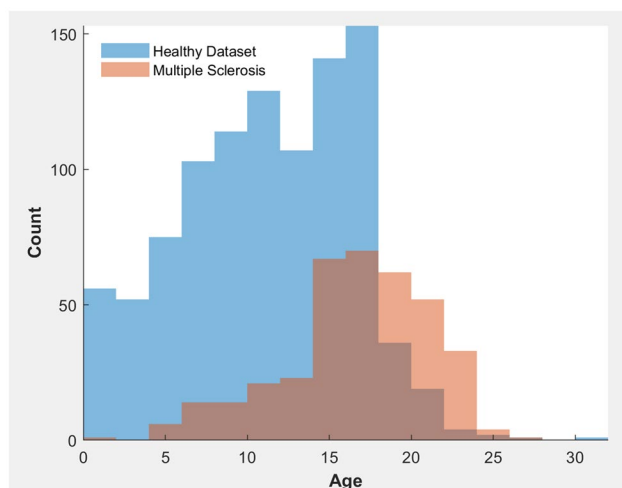
### 2.1 | Participants

Following approval by Boston Children's Hospital's (BCH) Institutional Review Board, the clinical imaging electronic database at BCH was reviewed for the present analysis from 01/01/2008 until 06/01/2016, and all the brain MRIs were included for further analysis after confirming a diagnosis of MS from the participant's electronic medical records. Shortcomings pertaining to the detail of information (and diagnostic criteria) available in participant's medical records are addressed in the discussion. Imaging acquisitions visually assessed as being of low quality (because of excessive participant motion, large metal artifact from a participant's dental hardware, lack of a T1 structural imaging volume providing diagnostically useful axial, sagittal and coronal oriented images etc.) were excluded from the study. Imaging acquisitions that were inaccessible for technical reasons were also excluded. This yielded 370 volumetric MRIs from 64 participants with a diagnosis of MS, of which 278 examinations were acquired from 47 participants diagnosed with relapsing remitting MS (RRMS), 1 examination was from a single patient with chronic progressive MS, and 91 were from 16 participants with MS whose subclassification was unavailable at the time of this study. MRIs were typically performed as part of monitoring the brain development in MS participants in an effort to find any new lesions on T2 imaging acquisitions, however, this investigation focuses on the clinical potential of T1 imaging in this population. Time intervals between scans for a given participant was typically approximately 1 year. We have not included very short interval scans, the most common example of which is that at our hospital, when a participant is imaged, the MR technicians often acquire up to three independent volumetric T1 imaging examinations per session. This is to ensure that at least one of the volumes are of sufficient diagnostic quality, and is often performed when motion artifacts are noticed on the

first T1 volumetric image set. In these situations, only one T1 MRI volume is selected for the analysis based on image quality. MRIs from the neurotypical cohort were assembled retrospectively by selecting participants on the basis of a normal MRI, as assessed by a BCH neuroradiologist, and whose medical records provided no indication of any neurological problems (participants with any known disorder were excluded such as autism, cerebral palsy, traumatic brain injury, brain cancer, developmental delay, MS, tuberous sclerosis complex, stroke, neurofibromatosis, cortical dysplasia, epilepsy, attention deficit hyperactivity disorder, etc.). The same exclusion criteria applied to the MS population was also applied to the healthy controls, including the exclusion of very short interval scans. This yielded 993 volumetric MRIs that act as healthy controls in this study (Levman et al., 2017). The MS participants ranged in age from 0 to 28 years old and the neurotypical participants ranged in age from 0 to 32 years old. Histograms demonstrating the age distributions (in years) for both the healthy and MS groups are provided in Figure 1.

## 2.2 | MRI data acquisition and preprocessing

Imaging was performed with clinical 3 Tesla MRI scanners (Skyra, Siemens Medical Systems, Erlangen, Germany) at BCH yielding T1 structural volumetric images accessed through the Children's Research and Integration System (Pienaar et al., 2014). Technical specifications regarding data acquisition and preprocessing are provided in additional detail in the Supporting Information.



**FIGURE 1** Histogram demonstrating the age distributions (in years) of the participants. Blue represents the healthy group while red represents the multiple sclerosis group [Colour figure can be viewed at [wileyonlinelibrary.com](http://wileyonlinelibrary.com)]

## 2.3 | Statistical analysis

This study included the acquisition of 2,893 measurements (cortical thicknesses, volumetric measurements, surface area, and surface curvature measurements) per volumetric imaging acquisition, as extracted by FreeSurfer (Fischl, 2012). All statistical analyses were performed in MATLAB (R2018a, Natick, MA, USA). In order to correct for the effect of performing multiple comparisons, we have employed the Bonferroni correction, with the 2,893 comparisons yielding a Bonferroni-corrected threshold for statistical significance  $p < .05/2,893 = 1.728e^{-5}$ . Statistical testing was computed using the standard  $t$  test (Student, 1908) for two groups of samples. Cohen's  $d$  statistic was computed to assess the effect sizes for all considered biomarker measurements in a group-wise manner comparing our healthy and MS participants in each age range considered. Receiver operating characteristic (ROC) curve analysis was performed for each measurement to assess its diagnostic potential as a single biomarker, through the diagnostic statistical metric referred to as the area under the ROC curve (AUC) (Youngstrom, 2014). Multivariate regression was employed to control for variables potentially influencing our findings; more detail can be found in the Supporting Information.

## 3 | RESULTS

The age distributions for both healthy and POMS groups are provided in a histogram in Figure 1. Comparison of participants with MS and control participants at various age ranges demonstrates several regions exhibiting group-wise differences with large effect sizes (see Table 1). This resulted in 35% of our biomarker measurements exceeding the Bonferroni-corrected threshold for statistical significance. Table 1 is sorted such that the first item on the list exhibits the largest magnitude of the effect size. All data points presented in Table 1 represent statistically significant findings based on the Bonferroni correction for multiple comparisons. The largest differences found between MS and control groups involved measures of ventricular and CSF volumes as well as reduced average cortical thicknesses. Additional differences were observed across multiple brain sub-regions in biomarkers measuring surface area, surface curvature, the standard deviation of cortical thicknesses, volume of white matter hypointensities, gray matter (GM) volumes, and some small effects associated with regional white matter volumes. General trends in the biomarkers show MS participants present with decreased average cortical thickness, GM volumes, white matter (WM) volumes, and surface areas while having increased surface curvature, increased WM hypointensities, and increased variability in cortical thickness, as measured by the standard deviation. Although most of the studied

**TABLE 1** Age-dependent summary of the leading abnormalities identified in our multiple sclerosis population. Cohen's *d* statistic is provided followed by the area under the receiver operating characteristic curve (AUC) in brackets

Regional measurement	Cohen's <i>d</i> statistic (AUC)
Parahippocampal average thickness	L -0.92 (0.76), R -0.98 (0.78)
Third ventricle volume	0.94 (0.76)
Lateral ventricle volume	L 0.80 (0.75), R 0.91 (0.77)
Medial occipital temporal and lingual sulci average thickness	L -0.87 (0.75), R -0.90 (0.76)
Paracentral average thickness	L -0.79 (0.73), R -0.89 (0.76)
Parahippocampal part of the medial occipito-temporal gyrus average thickness	L -0.89 (0.76), R -0.80 (0.72)
Cerebrospinal fluid volume	0.87 (0.75)
Superior parietal average thickness	L -0.79 (0.73), R -0.87 (0.76)
Superior temporal average thickness	L -0.80 (0.72), R -0.86 (0.76)
Whole hemisphere average thickness	L -0.85 (0.74), R -0.86 (0.75)
Precuneus average thickness	L -0.85 (0.75), R -0.86 (0.76)
Fusiform average thickness	L -0.76 (0.73), R -0.86 (0.76)
Posterior ramus of the lateral sulcus average thickness	L -0.80 (0.73), R -0.85 (0.76)
Isthmus cingulate average thickness	L -0.84 (0.75), R -0.79 (0.73)
Transverse temporal average thickness	L -0.70 (0.70), R -0.84 (0.75)
Choroid plexus volume	L 0.83 (0.74), R 0.76 (0.70)
Middle posterior cingulate gyrus and sulcus average thickness	L -0.68 (0.70), R -0.82 (0.74)
Superior frontal gyrus average thickness	L -0.72 (0.71), R -0.80 (0.73)
Planum temporale average thickness	L -0.79 (0.72), R -0.80 (0.73)
Posterior dorsal cingulate gyrus average thickness	L -0.80 (0.73), R -0.70 (0.72)
Superior temporal sulcus average thickness	L -0.73 (0.71), R -0.79 (0.73)
Posterior ventral cingulate gyrus average thickness	L -0.79 (0.73), R -0.57 (0.67)
Anterior transverse temporal gyrus average thickness	L -0.70 (0.70), R -0.78 (0.73)

(Continues)

**TABLE 1** (Continued)

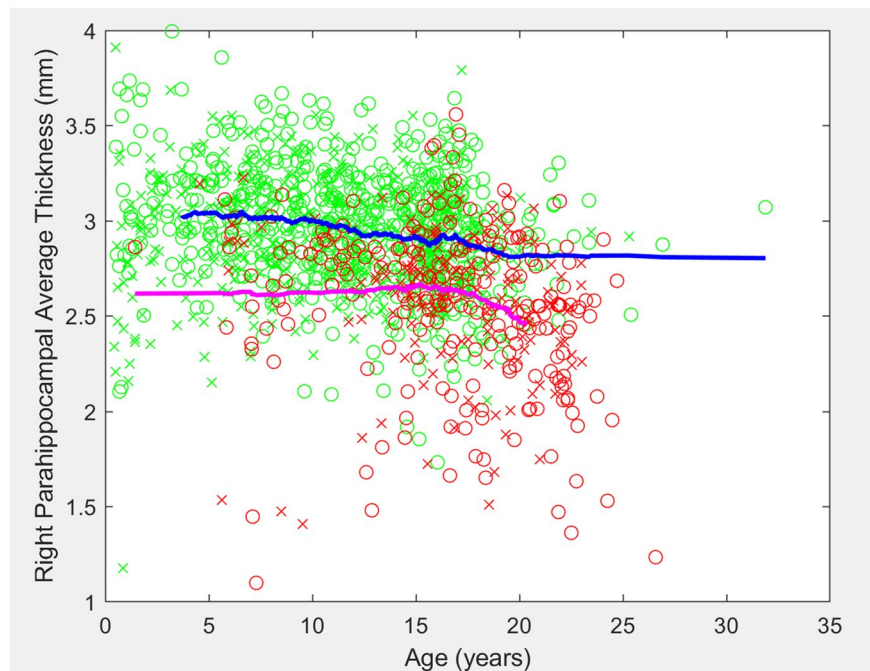
Regional measurement	Cohen's <i>d</i> statistic (AUC)
Superior frontal average thickness	L -0.74 (0.71), R -0.77 (0.72)
Superior and transverse occipital sulci average thickness	L -0.73 (0.71), R -0.76 (0.72)
Supramarginal average thickness	L -0.76 (0.71), R -0.68 (0.70)
Brodman's area 2 average thickness	L -0.73 (0.71), R -0.76 (0.72)

Abbreviations: AUC, area under the receiver operating characteristic curve; L, left, R, right.

regions showed increased variability in cortical thickness, several brain regions (calcarine sulcus, Brodmann's area 3b, cuneus, and posterior cingulate) exhibited decreases in the variability of cortical thicknesses.

Measurements such as the right lateral ventricle and third ventricle volume had markedly large AUC (>0.70) and strong positive *d* statistic values, as expected of neurodegenerative diseases such as MS (Müller et al., 2013; Turner et al., 2001).

Biomarkers demonstrating group-wise differences were found in brain regions potentially associated with memory impairment such as the entorhinal cortex, parahippocampal gyrus, perirhinal cortex, and superior temporal gyrus. A scatter plot of the observed thicknesses of the right parahippocampal gyrus varying with patient age is provided in Figure 2. Although the leading biomarker measurements identified mostly represent decreased average cortical thicknesses (see Table 1), our analysis also included surface area (SA), surface curvature, cortical thickness variability (as measured with the standard deviation) and volumetric measurements. The leading cortical thickness variability measurements included increased standard deviations within the left fusiform region ( $d = 0.53$ ), the left perirhinal region ( $d = 0.52$ ), the left inferior circular sulcus of the insula ( $d = 0.52$ ), and decreased standard deviation in the calcarine sulcus ( $d = -0.55$ ). The observed SA measurements with the largest effect sizes in our analysis included decreased SA in the left superior temporal region ( $d = -0.39$ ), the left middle temporal region ( $d = -0.37$ ), and the left inferior temporal region ( $d = -0.38$ ). The surface curvature measurements with the largest effect sizes included increased average curvature in the left calcarine sulcus ( $d = 0.75$ ), the medial occipito-temporal and lingual sulci bilaterally (L:  $d = 0.69$ , R:  $d = 0.68$ ), and the left isthmus cingulate ( $d = 0.65$ ). Table 1 demonstrates abnormalities indicating increased volumes of the ventricles and the choroid plexus. Additional findings include bilateral hemispheric GM volume reductions (L:  $d = -0.72$ , R:  $d = -0.71$ ) observed to have the largest regional effects in the left superior temporal ( $d = -0.72$ ), right precuneus ( $d = -0.71$ ),



**FIGURE 2** Right parahippocampal average cortical thickness versus age for the neurotypical (green) and multiple sclerosis (red) participants. Males are represented with an X and females with an O [Colour figure can be viewed at [wileyonlinelibrary.com](http://wileyonlinelibrary.com)]

and the right superior temporal sulcus ( $d = -0.71$ ). Also of potential interest was an observed increase in the volume of WM hypointensities ( $d = 0.70$ ) in MS, a finding that may be linked with known demyelination and other processes, although WM hypointensities are known to be nonspecific in MS. All reported findings are based on statistical analysis of the raw measurements for ease of comparison with future work. Multivariate regression results confirmed that findings produced from the raw data presented in this analysis remained statistically significant according to the Bonferroni-adjusted threshold for statistical significance after adjusting or controlling for the effects of covariates with multivariate regression. Thus our multivariate analysis confirms that our findings were not the result of secondary effects of age, gender/sex, or brain volume.

## 4 | DISCUSSION

This study included a large-scale analysis of volumetric structural MRIs of the brains of POMS participants and healthy controls and demonstrated a wide variety of imaging features exhibiting group-wise differences (see Table 1). Biomarkers such as cortical thickness, ventricular volumes, and choroid plexus volumes demonstrated the strongest effect sizes and the largest AUC and are potentially related to various clinical features of MS.

The sub-regions displaying major reductions in cortical thickness and high AUC values are thought to play a role with facilitation of memory acquisition and information processing, one of the known cognitive impairments associated with MS (Archibald & Fisk, 2000; Benedict et

al., 2009; Chiaravalloti et al., 2008; Ekmekci et al., 2017; Rao et al., 1991, 1993; Takahashi et al., 2002). Additionally, a link between cortical thinning in the left superior temporal gyrus and cognitive dysfunction was also established (Achiron et al., 2013). The pathology underlying cortical thinning in MS is currently unknown, however, it is possible that demyelination of neurons due to MS contributes to decreased cortical thicknesses (Peterson et al., 2001; Vercellino et al., 2005) and leads to manifestation of symptoms. This may be supportive of the theory that there is a direct link between fiber tract structure and cortical thickness, with primary fiber tracts that extend into the GM potentially playing a direct role in supporting the structure of the cortex. When a major fiber tract undergoes demyelination, the structural integrity of its myelin sheath is compromised which may contribute to compromised support for the structure of the cortex. In MS, demyelination results in disintegration of myelin (Bjartmar et al., 1999), which may play a structural role in the fiber tract itself, which in turn might limit the fiber tract's ability to support the specific structure and conformation of the cortex. Reduced structural support to the cortex may be an underlying reason for the thinner cortices observed in MS. Disruption of parahippocampal WM pathways has been observed in Alzheimer's disease (Stoub et al., 2006), a condition for which reduced parahippocampal cortical thickness has also been reported (Krumm et al., 2016). It is possible that reduced parahippocampal thickness in MS is linked with disruption of parahippocampal WM integrity in MS, which has also been observed in the literature (Llufriu et al., 2014). The parahippocampal region has also been implicated in playing a role in motor imagery (Malouin et al., 2003), which may be linked with known motor issues in MS.

Our finding exhibiting the largest effect size was a decreased average cortical thickness in the parahippocampal gyrus. This is in agreement with findings from previous cortical thickness research (Narayana et al., 2013; Steenwijk et al., 2016). Abnormalities of the parahippocampal gyrus can accompany hippocampal sclerosis (Ferreira et al., 2003) and abnormalities of both regions may be relevant to known symptoms of MS. The parahippocampal region and the connected hippocampal region, are known to play an important role in memory (Eichenbaum et al., 2007; van Strien et al., 2009; Yonelinas et al., 2001) and so abnormalities therein may be associated with known memory deficits in participants with MS (MacAllister et al., 2007; Rao et al., 1984). Indeed, several previous studies have reported abnormal presentation of the hippocampal region in MS (Anderson et al., 2010; Hulst et al., 2015; Longoni et al., 2015; Rocca et al., 2016; Sicotte et al., 2008), which may be representative of atrophy contributing to memory deficits. It has also been reported that disruption of parahippocampal WM pathways contributes to memory decline in elderly individuals with mild cognitive impairment by partially disconnecting the hippocampus from incoming sensory information (Stoub et al., 2006). It has been theorized that neural fiber tracts may play an important role in resulting cortical thicknesses (CT). Reduced parahippocampal cortical thickness was also observed to be associated with increased average curvature on the surface of the parahippocampal gyrus (L:  $d = 0.54$ ; R:  $d = 0.45$ ), which may be linked with increased gyrification associated with variable levels of compromise to the WM tracts projecting into the cortex. We have also observed modestly increased cortical thickness variability in the parahippocampal gyrus which may further illustrate the same underlying effect (L:  $d = 0.25$ ; R:  $d = 0.25$ ). Additionally, we observed statistically significantly reduced cortical thicknesses ( $d = -0.73$ ) in the entorhinal region, which is known to be involved in working memory.

Comparison of our findings with the scientific literature on cortical thinning in MS confirms previously reported strong parahippocampal and entorhinal cortical thinning (Narayana et al., 2013), with left entorhinal cortex thickness being affected to a greater extent than the right. We observed bilateral decreases in the superior temporal gyrus' cortical thickness, consistent with literature findings (Achiron et al., 2013; Sailer et al., 2003; Steenwijk et al., 2016). Additionally, reduced cortical thickness was observed in the left perirhinal cortex ( $d = 0.52$ ). To the best of our knowledge, cortical thinning in this structure has not been documented in the literature previously. The perirhinal cortex is composed of Brodmann's area 35 and 36 and is known to be involved in memory function (Brown & Aggleton, 2001).

In addition to measuring cortical thickness, several brain sub-regions displayed increased variability in cortical thickness, as measured by the standard deviation, including the left

fusiform region ( $d = 0.53$ ), the left perirhinal region (0.52), and the left inferior circular sulcus of the insula ( $d = 0.52$ ) as well as *decreased* standard deviation in the calcarine sulcus ( $d = -0.55$ ). This is the first time such findings have been reported in the literature. These variables exhibited moderate effect sizes and may be indicative of underlying structural abnormalities present in individuals with MS. It is possible that the increased variability in these regions, such as the fusiform gyrus and the insula, is linked with emotional processing impairments known to be associated with MS (Phillips et al., 2011), further investigation of which can be addressed with future work on additional datasets that include extensive clinical patient variables.

Discussion of the volumetric findings, asymmetries, the statistical analyses employed in this study, as well as limitations of the present analysis are addressed in the Supporting Information.

## 5 | CONCLUSION

The main strengths of this study are its large scale, in terms of the number of examinations included, the demonstration that MS structural abnormalities are detectable clinically, and thorough consideration of a large collection of biomarker measurements provided by FreeSurfer (Fischl, 2012), as opposed to studies focused on single biomarker types. Our results indicate that automatically extracted biomarkers can be used to predict the pathological status of a participant whose brain has been imaged with MRI, however, more work is needed to optimize the performance of such a test. We demonstrate several biomarkers with strong discriminating power between POMS and healthy groups, however, more work is needed to optimize any diagnostic technology that relies upon these findings. Future work will look to improve our ability to discriminate between POMS and healthy participants with the help of additional MRI modalities, such as tractography and functional MRI (fMRI) as well as with multivariate analysis.

## ETHICS APPROVAL AND PATIENT CONSENT STATEMENT

This study was approved by the research ethics boards of both institutions involved in the research. Patient consent was waived by the ethics review due to the retrospective nature of this study providing no risk to the patients.

## ACKNOWLEDGEMENTS

The authors thank Dr. Henry Feldman, Principal Biostatistician at Boston Children's Hospital for advice on conducting statistical analyses. This work was supported by the National Institutes

of Health (grant numbers R01HD078561, R21MH118739, HD098606, and R03NS091587) to ET; Natural Science and Engineering Research Council of Canada's Canada Research Chair grant (grant number 231266) to JL, a Canada Foundation for Innovation and Nova Scotia Research and Innovation Trust infrastructure grant (R0176004) to JL, a Natural Science and Engineering Research Council of Canada Discovery Grant (R0192004) to JL, and a St. Francis Xavier University research startup grant to JL (grant number R0168020).

## CONFLICT OF INTEREST

The authors have no conflict of interest to report associated with this study.

## AUTHOR CONTRIBUTIONS

Data acquisition and preprocessing: Avilash Das, Jacob Levman, and Patrick MacDonald; Statistical Analysis: Avilash Das and Jacob Levman; Manuscript Authoring and Editing: Avilash Das, Jacob Levman, Allissa MacDonald, Lindsay Berrigan, and Emi Takahashi.

## DATA AVAILABILITY STATEMENT

In accordance with our ethics approval documentation, the clinical MRI examinations relied upon in this analysis are not publically available.

## ORCID

Jacob Levman  <https://orcid.org/0000-0002-9604-3157>

## REFERENCES

- Achiron, A., Chapman, J., Tal, S., Bercovich, E., Gil, H., & Achiron, A. (2013). Superior temporal gyrus thickness correlates with cognitive performance in multiple sclerosis. *Brain Structure and Function*, 218(4), 943–950.
- Archibald, C. J., & Fisk, J. D. (2000). Information processing efficiency in participants with multiple sclerosis. *Journal of Clinical and Experimental Neuropsychology*, 22(5), 686–701.
- Anderson, V., Fisniku, L., Khaleeli, Z., Summers, M., Penny, S., Altmann, D., Thompson, A., Ron, M., & Miller, D. (2010). Hippocampal atrophy in relapsing-remitting and primary progressive MS: A comparative study. *Multiple Sclerosis Journal*, 16(9), 1083–1090.
- Bakshi, R., Benedict, R. H., Bermel, R. A., & Jacobs, L. (2001). Regional brain atrophy is associated with physical disability in multiple sclerosis: Semiquantitative magnetic resonance imaging and relationship to clinical findings. *Journal of Neuroimaging*, 11(2), 129–136.
- Bakshi, R., Thompson, A. J., Rocca, M. A., Pelletier, D., Dousset, V., Barkhof, F., Ingles, M., Guttman, C. R., Horsfield, M. A., & Filippi, M. (2008). MRI in multiple sclerosis: Current status and future prospects. *The Lancet Neurology*, 7(7), 615–625.
- Benedict, R. H. B., Ramasamy, D., Munschauer, F., Weinstock-Guttman, B., & Zivadinov, R. (2009). Memory impairment in multiple sclerosis: Correlation with deep grey matter and mesial temporal atrophy. *Journal of Neurology, Neurosurgery and Psychiatry*, 80(2), 201–206.
- Bergsland, N., Horakova, D., Dwyer, M. G., Dolezal, O., Seidl, Z. K., Vaneckova, M., Krasensky, J., Havrdova, E., & Zivadinov, R. (2012). Subcortical and cortical gray matter atrophy in a large sample of participants with clinically isolated syndrome and early relapsing-remitting multiple sclerosis. *American Journal of Neuroradiology*, 33(8), 1573–1578.
- Bermel, R. A., Innus, M. D., Tjoa, C. W., & Bakshi, R. (2003). Selective caudate atrophy in multiple sclerosis: A 3D MRI parcellation study. *NeuroReport*, 14(3), 335–339.
- Brown, M. W., & Aggleton, J. P. (2001). Recognition memory: What are the roles of the perirhinal cortex and hippocampus? *Nature Reviews Neuroscience*, 2, 51–61.
- Bjartmar, C., Yin, X., & Trapp, B. D. (1999). Axonal pathology in myelin disorders. *Journal of Neurocytology*, 28(4–5), 383–395.
- Ceccarelli, A., Rocca, M. A., Pagani, E., Colombo, B., Martinelli, V., Comi, G., & Filippi, M. (2008). A voxel-based morphometry study of grey matter loss in MS participants with different clinical phenotypes. *NeuroImage*, 42(1), 315–322.
- Chiaravalloti, N. D., & DeLuca, J. (2008). Cognitive impairment in multiple sclerosis. *The Lancet Neurology*, 7, 1139–1151.
- Deppe, M., Krämer, J., Tenberge, J. G., Marinell, J., Schwindt, W., Deppe, K., Groppa, S., Wiendl, H., & Meuth, S. G. (2016). Early silent microstructural degeneration and atrophy of the thalamocortical network in multiple sclerosis. *Human Brain Mapping*, 37(5), 1866–1879.
- Ekmekci, O. (2017). Pediatric multiple sclerosis and cognition: A review of clinical, neuropsychologic, and neuroradiologic features. *Behavioural Neurology*, 1463570.
- Eichenbaum, H., Yonelinas, A. R., & Ranganath, C. (2007). The medial temporal lobe and recognition memory. *Annual Review of Neuroscience*, 30, 123–152.
- Fischl, B. (2012). FreeSurfer. *NeuroImage*, 62(2), 774–781.
- Ferreira, N. F., de Oliveira, V., Amaral, L., Mendonca, R., & Lima, S. S. (2003). Analysis of parahippocampal gyrus in 115 participants with hippocampal sclerosis. *Arquivos de Neuro-Psiquiatria*, 61(3), 707–711.
- Filippi, M., Brück, W., Chard, D., Fazekas, F., Geurts, J. J., Enzinger, C., Hametner, S., Kuhlmann, T., Preziosa, P., Rovira, À., & Schmierer, K. (2012). Association between pathological and MRI findings in multiple sclerosis. *Lancet Neurology*, 11, 349–360.
- Ge, Y., Jensen, J. H., Lu, H., Helpert, J. A., Miles, L., Ingles, M., Babb, J. S., Herbert, J., & Grossman, R. I. (2007). Quantitative assessment of iron accumulation in the deep gray matter of multiple sclerosis by magnetic field correlation imaging. *American Journal of Neuroradiology*, 28(9), 1639–1644.
- Henry, R. G., Shieh, M., Okuda, D. T., Evangelista, A., Gorno-Tempini, M. L., & Pelletier, D. (2008). Regional grey matter atrophy in clinically isolated syndromes at presentation. *Journal of Neurology, Neurosurgery and Psychiatry*, 79(11), 1236–1244.
- Houtchens, M. K., Benedict, R. H., Killiany, R., Sharma, J., Jaisani, Z., Singh, B., Weinstock-Guttman, B., Guttman, C. R., & Bakshi, R. (2007). Thalamic atrophy and cognition in multiple sclerosis. *Neurology*, 69(12), 1213–1223.
- Hulst, H. E., Schoonheim, M. M., van Geest, Q., Uitdehaag, B. M. J., Barkhof, F., & Geurts, J. J. G. (2015). Memory impairment in multiple sclerosis: Relevance of hippocampal activation and hippocampal connectivity. *Multiple Sclerosis*, 21(13), 1705–1712.

- Krumm, S., Kivisaari, S. L., Probst, A., Monsch, A. U., Reinhardt, J., Ulmer, S., Stippich, C., Kressig, R. W., & Taylor, K. I. (2016). Cortical thinning of parahippocampal subregions in very early Alzheimer's disease. *Neurobiology of Aging*, *38*, 188–196.
- Levman, J., MacDonald, P., Lim, A. R., Forgeron, C., & Takahashi, E. (2017). A pediatric structural MRI analysis of healthy brain development from newborns to young adults. *Human Brain Mapping*, *38*(12), 5931–5942.
- Llufriu, S., Martinez-Heras, E., Fortea, J., Blanco, Y., Berenguer, J., Gabilondo, I., Ibarretxe-Bilbao, N., Falcon, C., Sepulveda, M., Solavalls, N., Bargallo, N., Graus, F., Villoslada, P., & Saiz, A. (2014). Cognitive functions in multiple sclerosis: Impact of gray matter integrity. *Multiple Sclerosis Journal*, *20*(4), 424–432.
- Longoni, G., Rocca, M., Pagani, E., Riccitelli, G., Colombo, B., Rodegher, M., Falini, A., Comi, G., & Filippi, M. (2015). Deficits in memory and visuospatial learning correlate with regional hippocampal atrophy in MS. *Brain Structure and Function*, *220*(1), 435–444.
- MacAllister, W. S., Christodoulou, C., Milazzo, M., & Krupp, L. B. (2007). Longitudinal neuropsychological assessment in pediatric multiple sclerosis. *Developmental Neuropsychology*, *32*(2), 625–644.
- Malouin, F., Richards, C. L., Jackson, P. L., Dumas, F., & Doyon, J. (2003). Brain activations during motor imagery of locomotor-related tasks: A PET study. *Human Brain Mapping*, *19*(1), 47–62.
- Mesaros, S., Rovaris, M., Pagani, E., Pulizzi, A., Caputo, D., Ghezzi, A., Bertolotto, A., Capra, R., Falautano, M., Martinelli, V., Comi, G., & Filippi, M. (2008). A magnetic resonance imaging voxel-based morphometry study of regional gray matter atrophy in participants with benign multiple sclerosis. *Archives of Neurology*, *65*(9), 1223–1230.
- Müller, M., Esser, R., Kötter, K., Voss, J., Müller, A., & Stellmes, P. (2013). Third ventricular enlargement in early stages of multiple sclerosis is a predictor of motor and neuropsychological deficits: A cross-sectional study. *British Medical Journal Open*, *3*(9), e003582.
- Narayana, P. A., Govindarajan, K. A., Goel, P., Datta, S., Lincoln, J. A., Cofield, S. S., Cutter, G. R., Lublin, F. D., & Wolinsky, J. S. (2013). Regional cortical thickness in relapsing remitting multiple sclerosis: A multi-center study. *NeuroImage: Clinical*, *2*, 120–131.
- Parmar, K., Banwell, B., Akbar, N., & Bigi, S. (2018). Imaging pediatric multiple sclerosis—Challenges and recent advances. *Neuropediatrics*, *49*, 165–172.
- Phillips, L. H., Henry, J. D., Scott, C., Summers, F., Whyte, M., & Cook, M. (2011). Specific impairments of emotion perception in multiple sclerosis. *Neuropsychology*, *25*(1), 131–136.
- Pienaar, R., Rannou, N., Haehn, D., & Grant, P. E. (2014). ChRIS: Real-time web-based MRI data collection analysis, and sharing. In *20th Annual Meeting of the Organization for Human Brain Mapping (OHBM)*, *5*, <https://doi.org/10.7490/F1000RESEARCH.1096291.1>.
- Peterson, J. W., Bö, L., Mörk, S., Chang, A., & Trapp, B. D. (2001). Transected neurites, apoptotic neurons, and reduced inflammation in cortical multiple sclerosis lesions. *Annals of Neurology*, *50*, 389–400.
- Rao, S. M., Hammeke, T. A., McQuillen, M. P., Khatri, B. O., & Lloyd, D. (1984). Memory disturbance in chronic progressive multiple sclerosis. *Archives of Neurology*, *41*(6), 625–631.
- Rao, S. M., Leo, G. J., Bernardin, L., & Unverzagt, F. (1991). Cognitive dysfunction in multiple sclerosis I. Frequency, patterns, and prediction. *Neurology*, *41*(5), 685–691.
- Rao, S. M., Grafman, J., DiGuilio, D., Mittenberg, W., Bernardin, L., Leo, G. J., Luchetta, T., & Unverzagt, F. (1993). Memory dysfunction in multiple sclerosis: Its relation to working memory, semantic encoding and implicit learning. *Neuropsychology*, *7*, 364–374.
- Renoux, C., Vukusic, S., Mikaeloff, Y., Edan, G., Clanet, M., Dubois, B., Debouverie, M., Brochet, B., Lebrun-Frenay, C., Pelletier, J., & Moreau, T. (2007). Adult Neurology Department KIDMUS Study Group. Natural history of multiple sclerosis with childhood onset. *New England Journal of Medicine*, *356*(25), 2603–2613.
- Riccitelli, G., Rocca, M. A., Pagani, E., Martinelli, V., Radaelli, M., Falini, A., Comi, G., & Filippi, M. (2012). Mapping regional grey and white matter atrophy in relapsing-remitting multiple sclerosis. *Multiple Sclerosis Journal*, *18*(7), 1027–1037.
- Rocca, M. A., Morelli, M. E., Amato, M. P., Momiola, L., Ghezzi, A., Veggioni, P., Capra, R., Pagani, E., Portaccio, E., Fiorino, A., Pippolo, L., Pera, M. C., Comi, G., Falini, A., & Filippi, M. (2016). Regional hippocampal involvement and cognitive impairment in pediatric multiple sclerosis. *Multiple Sclerosis Journal*, *22*(5), 628–640.
- Sailer, M., Fischl, B., Salat, D., Tempelmann, C., Schönfeld, M. A., Busa, E., Bodammer, N., Heinze, H. J., & Dale, A. (2003). Focal thinning of the cerebral cortex in multiple sclerosis. *Brain*, *126*, 1734–1744.
- Sepulcre, J., Sastre-Garriga, J., Cercignani, M., Ingle, G. T., Miller, D. H., & Thompson, A. J. (2006). Regional gray matter atrophy in early primary progressive multiple sclerosis: A voxel-based morphometry study. *Archives of Neurology*, *63*(8), 1175–1180.
- Sicotte, N. L., Kern, K. C., Giesser, B. S., Arshanapalli, A., Schultz, A., Montag, M., Wang, H., & Bookheimer, S. Y. (2008). Regional hippocampal atrophy in multiple sclerosis. *Brain*, *131*(4), 1134–1141.
- Steenwijk, M. D., Geurts, J. J., Daams, M., Tijms, B. M., Wink, A. M., Balk, L. J., Tewarie, P. K., Uitdehaag, B. M., Barkhof, F., Vrenken, H., & Pouwels, P. J. (2016). Cortical atrophy patterns in multiple sclerosis are non-random and clinically relevant. *Brain*, *139*(1), 115–126.
- Stoub, T. R., deToledo-Morrell, L., Stebbins, G. T., Leurgans, S., Bennett, D. A., & Shah, R. C. (2006). Hippocampal disconnection contributes to memory dysfunction in individuals at risk for Alzheimer's disease. *Proceedings of the National Academy of Sciences*, *103*(26), 10041–10045.
- Student, S. (1908). The probable error of a mean. *Biometrika*, *6*(1), 1–25.
- Takahashi, E., Ohki, K., & Miyashita, Y. (2002). The role of the parahippocampal gyrus in source memory for external and internal events. *NeuroReport*, *13*(15), 1951–1956.
- Turner, B., Ramli, N., Blumhardt, L. D., & Jaspan, T. (2001). Ventricular enlargement in multiple sclerosis: A comparison of three-dimensional and linear MRI estimates. *Neuroradiology*, *43*(8), 608–614.
- van Strien, N. M., Cappaert, N. L. M., & Witter, M. P. (2009). The anatomy of memory: An interactive overview of the parahippocampal-hippocampal network. *Nature Reviews Neuroscience*, *10*, 272–282.
- Vercellino, M., Plano, F., Votta, B., Mutani, R., Giordana, M. T., & Cavalla, P. (2005). Grey matter pathology in multiple sclerosis. *Journal of Neuropathology & Experimental Neurology*, *64*, 1101–1107.
- Yonelinas, A. P., Hopfinger, J. B., Buonocore, M. H., Kroll, N. E., & Baynes, K. (2001). Hippocampal, parahippocampal and occipito-temporal contributions to associative and item recognition memory: An fMRI study. *NeuroReport*, *12*(2), 359–363.





Youngstrom, E. A. (2014). A primer on receiver operating characteristic analysis and diagnostic efficiency statistics for pediatric psychology: We are ready to ROC. *Journal of Pediatric Psychology*, 39(2), 204–221.

### SUPPORTING INFORMATION

Additional supporting information may be found online in the Supporting Information section.

**How to cite this article:** Levman J, Das A, MacDonald A, MacDonald P, Berrigan L, Takahashi E. Clinically detectable structural abnormalities in pediatric-onset multiple sclerosis: A large-scale magnetic resonance imaging analysis. *Int J Dev Neurosci*. 2021;81:200–208. <https://doi.org/10.1002/jdn.10090>